INTERNATIONAL JOURNAL
of PEDIATRIC DERMATOLOGY

Vol. 3, Iss. 1, 2026
ISSN 3035-1006 online

Case Report

Pityriasis (Tinea) Versicolor in a Three-Month-Old Infant: A Case Report

Fabio Arcangeli[1] and Amalia Licordari[2]

[1]Dermatology, Guglielmo Marconi University, Rome, Italy;
[2]General Pediatrician, Reggio Calabria, Italy

KEYWORDS

Pityriasis versicolor, tinea versicolor, children, neonates, scalp, Malassezia

ABSTRACT

Pityriasis versicolor (PV) is a superficial fungal disease caused by Malassezia species, typically affecting adolescents and young adults and rarely reported in children and neonates. We describe a three-month-old infant presenting with hypopigmented macules on the face, trunk and scalp. Wood's light examination showed dull white areas and yellow green fluorescence consistent with active PV. This case, together with available literature, highlights that infantile and neonatal PV - though uncommon - may be frequently underestimated and the apparently unusual location on the scalp should always be considered.

CORRESPONDING AUTHOR

Prof. Fabio Arcangeli
Via G. Bordoni,
47922 Rimini, Italy
phone: +393357070145
email: fabio.arcangeli4@gmail.com

Copyright © by World Health Academy Publishing House
This publication and/or article is for individual use only and may not be further reproduced without written permission from the copyright holder.
Unauthorized reproduction may result in financial and other penalties
DISCLOSURE: ALL AUTHORS REPORT NO CONFLICTS OF INTEREST RELEVANT TO THIS ARTICLE.

1. Introduction

Pityriasis versicolor (PV), or tinea versicolor (TV), is a superficial fungal skin disease caused by Malassezia species (globosa, furfur or sympodialis), a common lipophilic yeast that is a saprophyte of human skin (1-4). Factors that lead to the conversion of saprophytic yeast into a parasitic form include genetic predisposition, warm and humid environments, use of oils and greasy topicals and seborrheic skin. Sometimes, immunosuppressive diseases or immunosuppressive drugs may play a causal role (5).

Due to the lipophilic nature of Malassezia, PV generally prefers the most seborrheic skin areas such as the upper trunk, the neck and sometimes the proximal part of the upper limbs, while more rarely it can affect the scalp and lower limbs (3, 4).

Although PV can occur at any age, it is more common among adolescents and young adults (1, 4, 5, 6). However, it has been reported several times in pediatric age (1, 7).

Clinically it presents with hypopigmented or less frequently hyperpigmented lenticular macules, sometimes confluent, with well-defined edges and often covered with fine desquamation. Examination with a Wood's light of the hypopigmented macules reveals a dull white color (melanopenic hypomelanosis) because the Wood's light is partially reflected and partially absorbed, and shows a characteristic yellow-green fluorescence in active forms (3, 4).

Despite the availability of effective local and systemic antifungal therapies, repeated recurrences are almost inevitable due to the saprophytic nature of the fungus involved and the frequent persistence or recurrence of the contributing factors.

We report here the case of a three-month-old child with a one-month history of hypopigmented macules distributed on the face, trunk, and scalp.

2. Case Report

A three-month-old boy was presented to our medical office with multiple hypopigmented macules on his face. Born through normal vaginal delivery at 38 weeks of gestation, he was in good health and had not taken any medications or applied any skin medications.

Physical examination revealed numerous lenticular hypopigmented macules distributed across the face, especially the forehead (Figure 1).

Wood's light examination revealed a typical yellow-green fluorescence of the macules, making them visible also on other parts of the body, such as the scalp and trunk (Figures 2, 3, 4).

After the diagnosis of PV the child was treated with miconazole 2% solution twice daily for two weeks with a favorable outcome (Figures 5, 6).

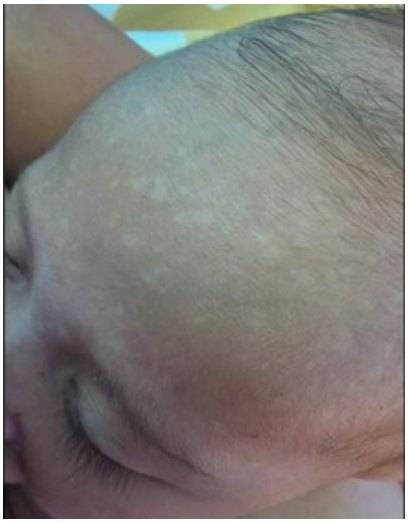

Figure 1. *Lenticular-shaped hypopigmented macules, partly confluent, on the forehead.*



Figure 2. *Wood's light examination. Yellow fluorescent spots on the forehead.*

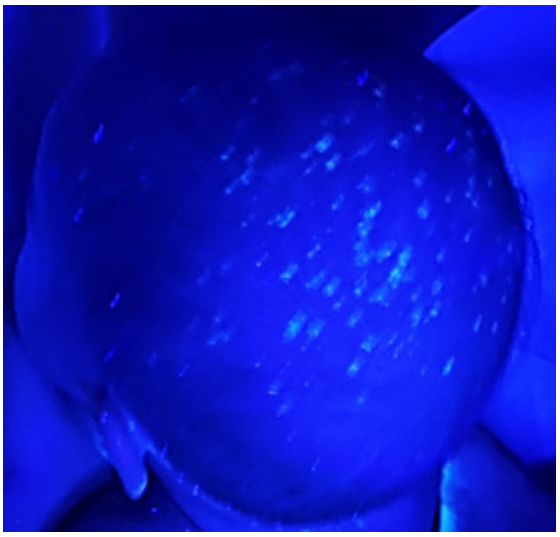

Figure 3. *Wood's light examination. Yellow fluorescent spots on the scalp.*



Figure 4. *Wood's light examination. Yellow fluorescent spots on the trunk.*



Figure 5. *Two weeks after antifungal therapy. The hypopigmented macules were no longer visible.*

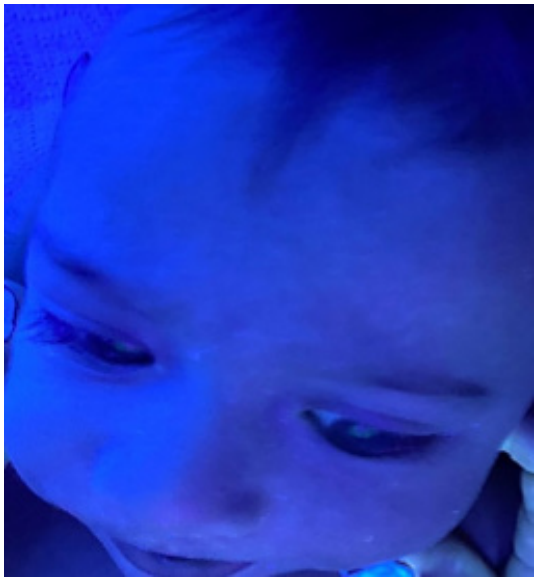

Figure 6. *wo weeks after antifungal therapy. Wood's light examination was negative.*

3. Discussion

PV is common in adolescents and young adults (3, 4) and less common in children. However, in a recent study, Luo Z et al. (1) reported 415 children with PV observed in just two years at their dermatological center. The age groups in which PV was common were younger than 6 months (35.42%) and 7 to 14 years (34.94%).

This may be due to the fact that the sebaceous glands are well developed at birth and, under the influence of maternal androgen hormones, they are extremely active from the first hours of life (8). Furthermore, human skin is colonized by Malassezia already at birth (9). Sebum production then gradually decreases, reaching low levels at about 6 months of age. At subsequent ages, the sebaceous glands have very low secretory activity until 6–7 years of age, when they start producing sebum again in increasing quantities (1, 9).

PV shows a slightly higher prevalence in males, likely attributed to increased sebaceous activity among them (1).

To our knowledge, before the study of Luo et al. (1), there were only 16 cases of PV reported in children under one year of age (5, 7, 10–16). Twelve were male and four female. Most diagnosed cases were in the 1–3 month age group, and no diagnosis was reported after the eighth month of life. The most commonly affected area was the face (the forehead), followed by the trunk and neck. The scalp was involved in only four cases.

In the pediatric age group, contrary to what happens in adulthood, the face is frequently affected. Luo Z et al. (1) found it in 65.29% of their cases. In our case, in addition to the face, the macules were diffusely present not only on the trunk, a commonly affected site in every age group, but also on the scalp.

The location of pityriasis versicolor lesions varies based on the individual's age, with the face and neck being more common sites in children. Scalp involvement is rare in both children and adults (17). In children of all ages, only a few cases of PV localized to the scalp, as in our case, are reported, and in children under one year of age, only three cases in addition to ours have been described (11, 16).

Wang et al. reported the case of a 7-year-old boy with PV on the scalp (18). In the study of Luo Z et al. (1), the scalp was affected in six children, and Zhou et al. (16) reported a series of four cases with hypopigmented lesions on the scalp, suggesting that we should not ignore scalp involvement in children with PV.

4. Conclusions

Contrary to previous assumptions, PV is not uncommon in the pediatric age group. In children under one year of age, it is likely underdiagnosed. Recognizing its clinical features and using Wood's light fluorescence are essential for a correct diagnosis. The most recent publications contribute to better defining the clinical spectrum of the disease in the pediatric age group, and in particular in the first months of life, highlighting a clear prevalence in the male sex, frequent localization on the face (particularly the forehead), and the not infrequent involvement of the scalp.

References

1. Luo Z, Li X, Zhou Z, Shi J, Chen H, Wang Y, et al. Pityriasis versicolor in the paediatric age group: a descriptive observational study of 415 children. Arch Dermatol Res. 2025;317(1):776. doi:10.1007/s00403-025-04276-x.
2. Camargo-Sánchez K, Toledo-Bahena M, Mena-Cedillos C, Ramirez-Cortes E, Toussaint-Caire S, Valencia-Herrera A, et al. Pityriasis versicolor in children and adolescents: an update. Curr Fungal Infect Rep. 2019;13(4):157-168. doi:10.1007/s12281-019-00361-3.
3. Leung AK, Barankin B, Lam JM, Leong KF, Hon KL. Tinea versicolor: an updated review. Drugs Context. 2022;11:2022-9-2. doi:10.7573/dic.2022-9-2.
4. Łabędź N, Navarrete-Dechent C, Kubisiak-Rzepczyk H, Bowszyc-Dmochowska M, Pogorzelska-Antkowiak A, Pietkiewicz P. Pityriasis versicolor—a narrative review on the diagnosis and management. Life (Basel). 2023;13(10):2097. doi:10.3390/life13102097.
5. Abdollahimajd F, Niknezhad N, Niknejad N, Nikvar M. Infantile hypopigmented pityriasis versicolor: two uncommon cases. Turk Pediatri Ars. 2019;54(4):277-280. doi:10.14744/TurkPediatriArs.2018.62134.
6. Parmar V, Madhudiya R. Multiple hypopigmented macules in a neonate. BMJ Case Rep. 2024;17(11):e263567. doi:10.1136/bcr-2024-263567.
7. Almalki MK, Alruwaili ZM, Alhammad NS, Alawadi TM, Dajam MS. Tinea versicolor in a three-month infant: a case report and review. Cureus. 2023;15(6):e40763. doi:10.7759/cureus.40763.
8. Shamloul G, Khachemoune A. An updated review of the sebaceous gland and its role in health and diseases part 1: embryology, evolution, structure, and function of sebaceous glands. Dermatol Ther. 2021;34(1):e14695. doi:10.1111/dth.14695.
9. Ianiri G, LeibundGut-Landmann S, Dawson TL Jr. Malassezia: a commensal, pathogen, and mutualist of human and animal skin. Annu Rev Microbiol. 2022;76:757-782. doi:10.1146/annurev-micro-040820-010114.
10. Nanda A, Kaur S, Bhakoo ON, Kaur I, Vaishnavi C. Pityriasis (tinea) versicolor in infancy. Pediatr Dermatol. 1988;5(4):260-262. doi:10.1111/j.1525-1470.1988.tb00900.x.
11. Di Silverio A, Zeccara C, Serra F, Ubezio S, Mosca M. Pityriasis versicolor in a newborn. Mycoses. 1995;38(5-6):227-2288. doi:10.1111/j.1439-0507.1995.tb00055.x.
12. Jubert E, Martín-Santiago A, Bernardino M, Bauzá A. Neonatal pityriasis versicolor. Pediatr Infect Dis J. 2015;34(3):329–330. doi: 10.1097/INF.0000000000000568.
13. Ben Said Z, Boussofara L, Saidi W, Ghariani N, Denguezli M, Belajouza C et al. Pityriasis versicolor in a 3-month-old boy. Arch Pediatr. 2010;17(8):1110–1111. doi: 10.1016/j.arcped.2010.04.004.
14. Congly H. Pityriasis versicolor in a 3-month-old boy. Can Med Assoc J. 1984;130(7):844–845.
15. Parisi M, Arcangeli F. A Newborn with Several White Spots on the Forehead. In: Arcangeli F, Lotti TM, editors. Clinical Cases in Neonatal and Infant Dermatology. Cham: Springer; 2022. p. 43–46. doi: 10.1007/978-3-030-91523-0_8.
16. Zhou YB, Chao JJ, Ma L, Xiao YY. Case Report: Scalp pityriasis versicolor may be a neglected problem. Front Pediatr. 2024;12:1361225. doi: 10.3389/fped.2024.1361225.
17. Leroy AK, Cortez de Almeida RF, Obadia DL, Frattini S, Melo DF. Scalp seborrheic dermatitis: what we know so far. Skin Appendage Disord. 2023;9(3):160–164. doi: 10.1159/000529854.
18. Wang L, Xing H. Pityriasis versicolor on the scalp: An unusual distribution of a common disease. Pediatr Investig. 2023;7(3):216–217. doi: 10.1002/ped4.12387.