



Case Report

Terra Firma-Forme Dermatosi (TFFD)

A. Iannone¹, L. Ciulli¹ and F. Arcangeli²

¹*Pediatrics, ATS Montagna, Sondrio, Italy;*

²*G. Marconi University, Rome, Italy*

KEYWORDS

Terra firma-forme dermatosis, Duncan's disease, pigmentation disorder, hyperpigmented patches, dirty skin

ABSTRACT

The authors report the case of a 4-month-old child of Moroccan origins affected by pigmentary dermatitis extending to the body and limbs whose clinical and dermoscopic characteristics allowed a hypothetical diagnosis of Terra Firma Forme Dermatosi. Rubbing with 70 % isopropyl alcohol caused the lesions to disappear, confirming the diagnosis. This condition, whose origin is still not well understood, is decidedly rare in the first months of life.

CORRESPONDING AUTHOR

Prof. Fabio Arcangeli,
Via G. Bordoni 16,
47922
Rimini (RN), Italy
Tel. +39.335.7070145
e-mail: fabio.arcangeli4@gmail.com

1. Introduction

Terra firma-forme dermatosis (TFFD), was first described in 1987 by Duncan as an acquired pigmentation disorder characterized by asymptomatic hyperpigmented patches or velvety plaques, which mimic the appearance of “dirty skin” (1). The anatomical sites most frequently affected are the trunk, extremities, neck and navel (2). TFFD affects both genders and all ages, although children and young adults have a higher risk

to being affected. The etiopathogenesis is unknown. Delayed maturation of keratinocytes resulting in epidermal retention of keratin material and melanin was suggested (3). Diagnosis is clinical (appearance of the lesions), dermatoscopic (brown polygonal scales similar to plates arranged in a mosaic or cobblestone pattern) and confirmed with the rubbing test with 70% isopropyl alcohol.

2. Case Description

We describe the case of a 4-month-old boy of Moroccan origin, with hyperpigmented patches, brownish in color, rough to the touch, localized on the trunk and limbs, associated with cutaneous xerosis (Fig. 1). Cleansing with soap and water was ineffective. Dermatoscopic examination showed numerous polygonal brownish clods arranged in mosaic (Fig. 2). The disappeared of the lesions after rubbing with gauze soaked in 70%

isopropyl alcohol (Fig. 3) confirmed the diagnosis of TFFD.

Considering the age of the child, skin xerosis and the wide spread of lesions, the home use of 10% urea cream was proposed with complete resolution. The age of the our child is unusual. The three youngest cases reported in the literature to date concern two girls aged 3 and 4 months and a boy aged 6 months (4-6).



Fig. 1. *Hyperpigmented brownish patches localized on the trunk and limbs.*

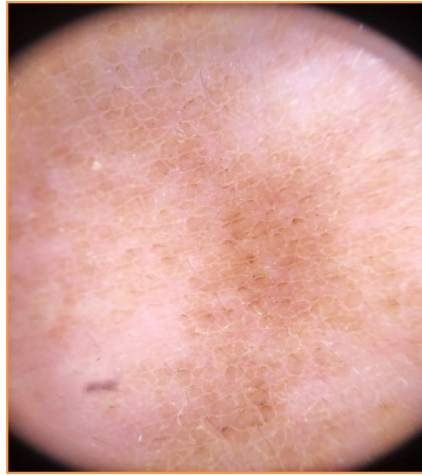


Fig. 2. *Dermatoscopic examination showed numerous polygonal brownish clods arranged in mosaic pattern.*

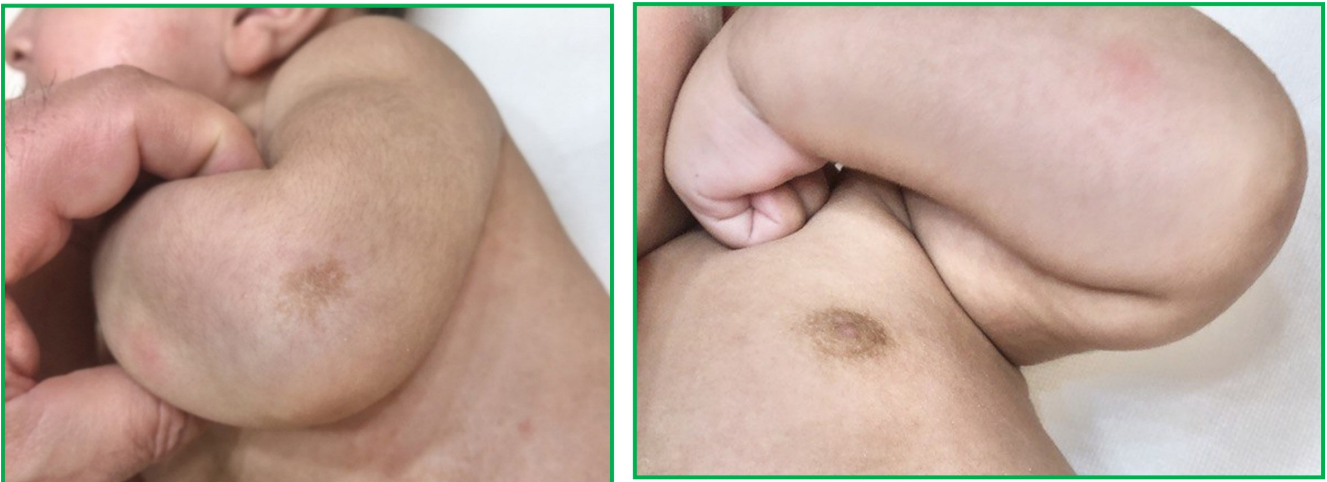

Fig. 3. *Before and after scrubbing with 70% isopropyl alcohol.*

3. Discussion

TFFD is a benign disease, very common but often underestimated. It is easy to recognize. Rubbing with 70% isopropyl alcohol is able to resolve pigmentation obtaining diagnostic and therapeutic results. It is thought that rubbing with alcohol may de-

nature cellular proteins, breaking down hyperkeratotic lesions (7). The main differential diagnosis is dermatosis neglecta, which resolves after cleaning with soap and water.

4. Conclusion

Despite numerous reports, TFFD remains an underestimated pathology, especially in the first years of life. The case we presented is one of the few reported in literature. Although this condition appears to be com-

pletely benign, it is important to be able to recognize it and to this end it is sufficient the simple rubbing with alcohol, avoiding unnecessary diagnostic tests.

References

1. Duncan WC, Tschien JA, Knox JM. Terra firma-forme dermatosis. *Arch Dermatol.* 1987;123:567-9.
2. Sechi A, Patrizi A, Savoia F, Leuzzi M, Guglielmo A, Neri I. Terra firma-forme dermatosis: a systematic review. *Int J Dermatol.* 2021;60(8):933-943.
3. Gusdorf L, Cribier B. Clinicopathological aspects of terra firma-forme dermatosis. *Ann Dermatol Venereol.* 2016;143:446-52.
4. Berk DR, Bruckner AL. Terra firma-forme dermatosis in a 4-month-old girl. *Pediatr Dermatol.* 2011; 28:79–81.
5. Özüğuz P, Kaçar SD, Kurtipek G, Akyurek F. The Early Onset Case of Terra Firma Forme Dermatosi. *Tıp Araştırmaları Dergisi.* 2015; 13(3):137-9.
6. Poço Miranda S, Silva CJ, Eiras I, Costa e Silva A, Correia Magalhães I, Rodrigues H, Teixeira V. Terra firma-forme dermatosis: an often underdiagnosed benign condition. *Eur J Pediatr Dermatol.* 2024;34 (1):48-50. <https://doi.org/10.26326/2281-9649.34.1.2540>
7. Badaró BA, Diniz LM, Nogueira PSE. Terra firma-forme dermatosis: an underdiagnosed condition. *Anais Brasileiros de Dermatologia.* 2020;95(3):397-9.